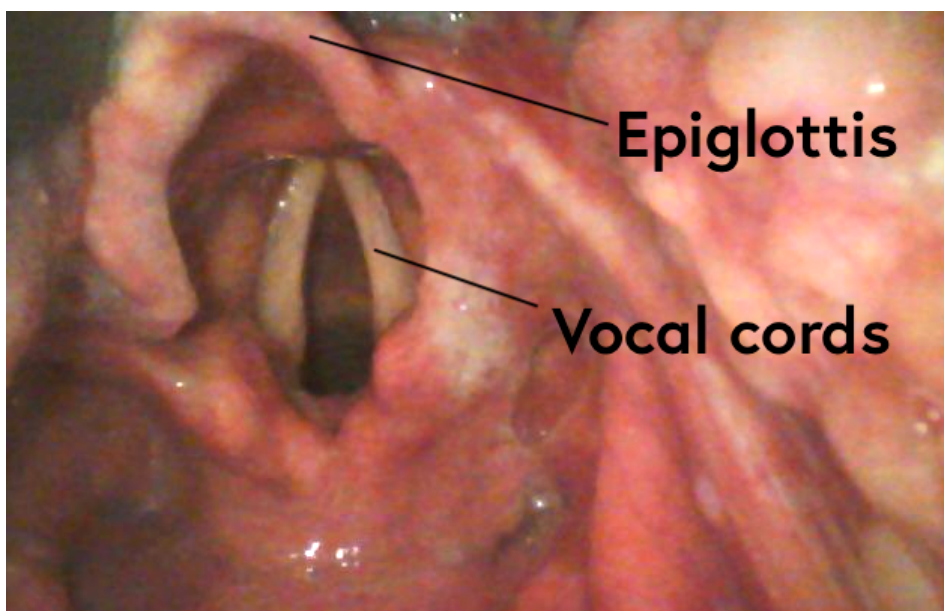


Anatomy of the Larynx

The larynx is an incredibly complex organ which allows human speech. It assists with coughing and straining, and closes the airway during swallowing to prevent aspiration. The larynx is at the level of the 3rd to 6th cervical vertebrae and extends from the epiglottis to the inferior border of the cricoid cartilage. It consists of 9 cartilages, the vocal cords and intrinsic and extrinsic musculature.

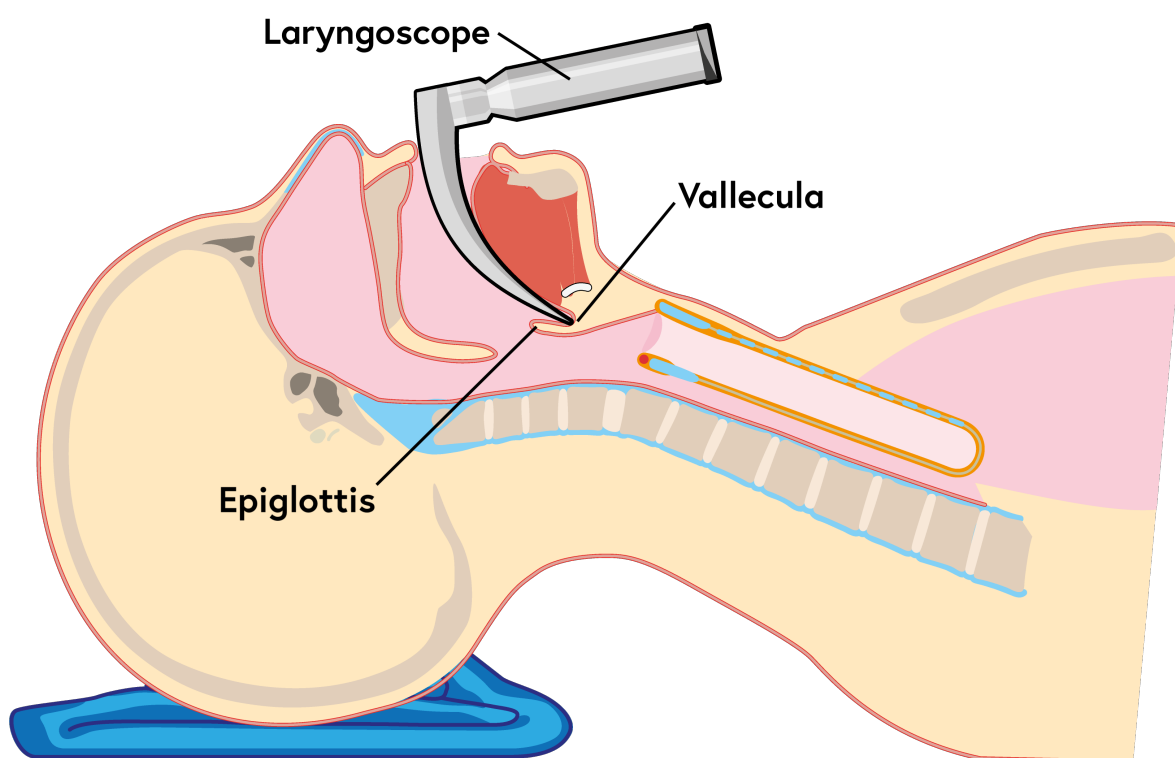
Glottis and Epiglottis

The glottis is the part of the larynx consisting of the vocal cords and the space between them. The epiglottis has evolved to shield the glottis from food heading for the oesophagus. On swallowing this muscular structure flips down like a lid to cover the glottis and prevent food entering the airway.



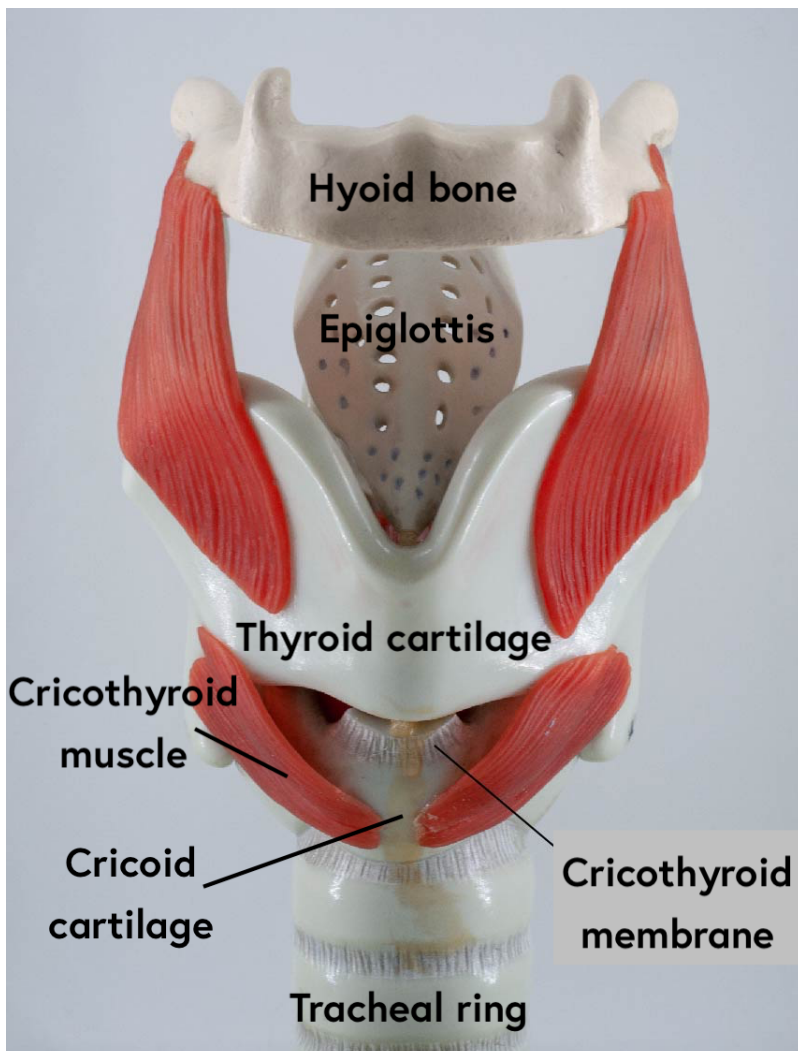
During laryngoscopy the epiglottis can obstruct a clear view of the vocal cords. If a laryngoscope is placed in the vallecula (a pouch like fold between the base of the tongue and the epiglottis) and drawn anteriorly, the epiglottis will lift to reveal the glottis.

Laryngoscopy demonstrating the laryngoscope blade placed in the vallecula to lift the epiglottis



Bones and cartilages

There are 9 cartilages of the larynx (3 single, 3 paired), and the hyoid is the only bone. The laryngeal cartilages consist of the single **thyroid**, **cricoid** and **epiglottis**, and pairs of **arytenoid**, **corniculate** and **cuneiform cartilages**. The steeper angle of the thyroid cartilage in men causes the vocal cords to be longer than in women, accounting for the deeper voice and greater laryngeal prominence (the Adam's apple).



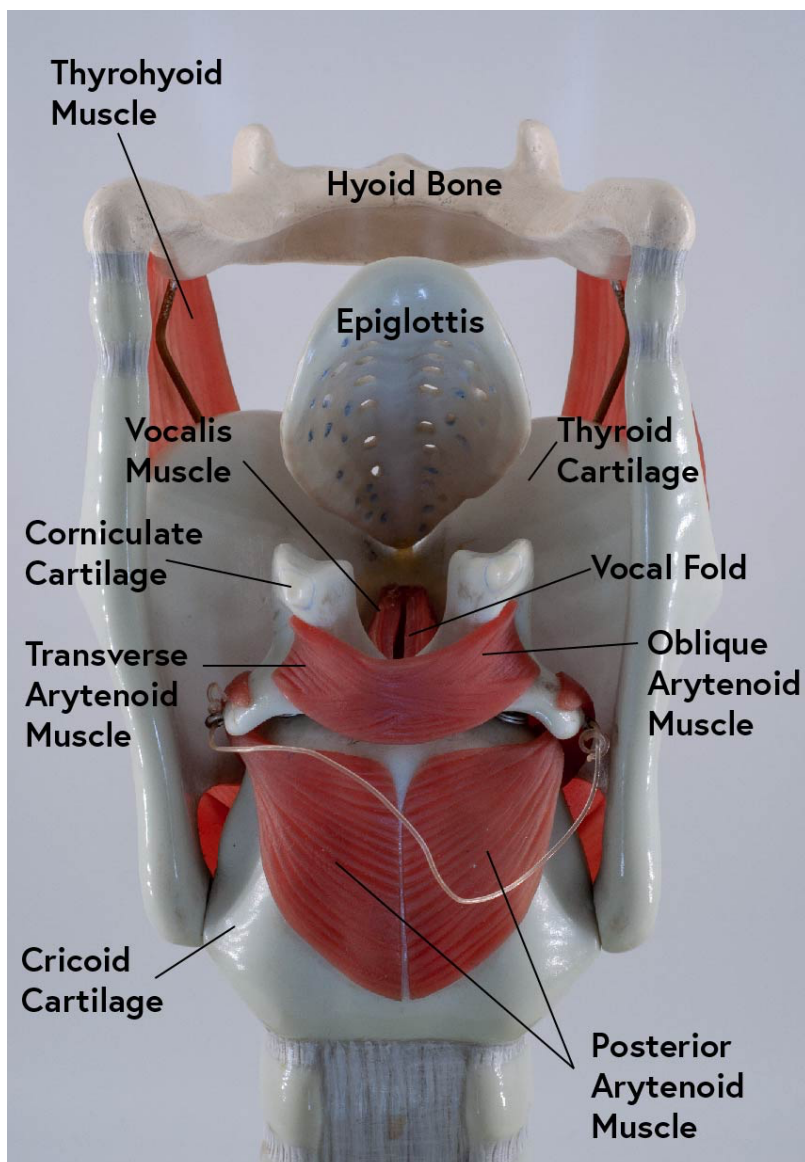
Anterior view of the Larynx (cartilages and muscles)

The thyroid cartilage articulates with the cricoid cartilage at the cricothyroid joint. The cricoid cartilage is shaped like a signet ring and since it is relatively strong and is the only complete ring of cartilage in the airway, it is here that cricoid pressure is exerted during rapid sequence induction.

The thyroid cartilage is connected to the cricoid cartilage anteriorly by the **cricothyroid membrane**. This is the site of front of neck access (FONA).

Movements of the thyroid, cricoid and arytenoid cartilages control the tension of the vocal cords.

Posterior view of the Larynx (cartilages and muscles)



Muscles

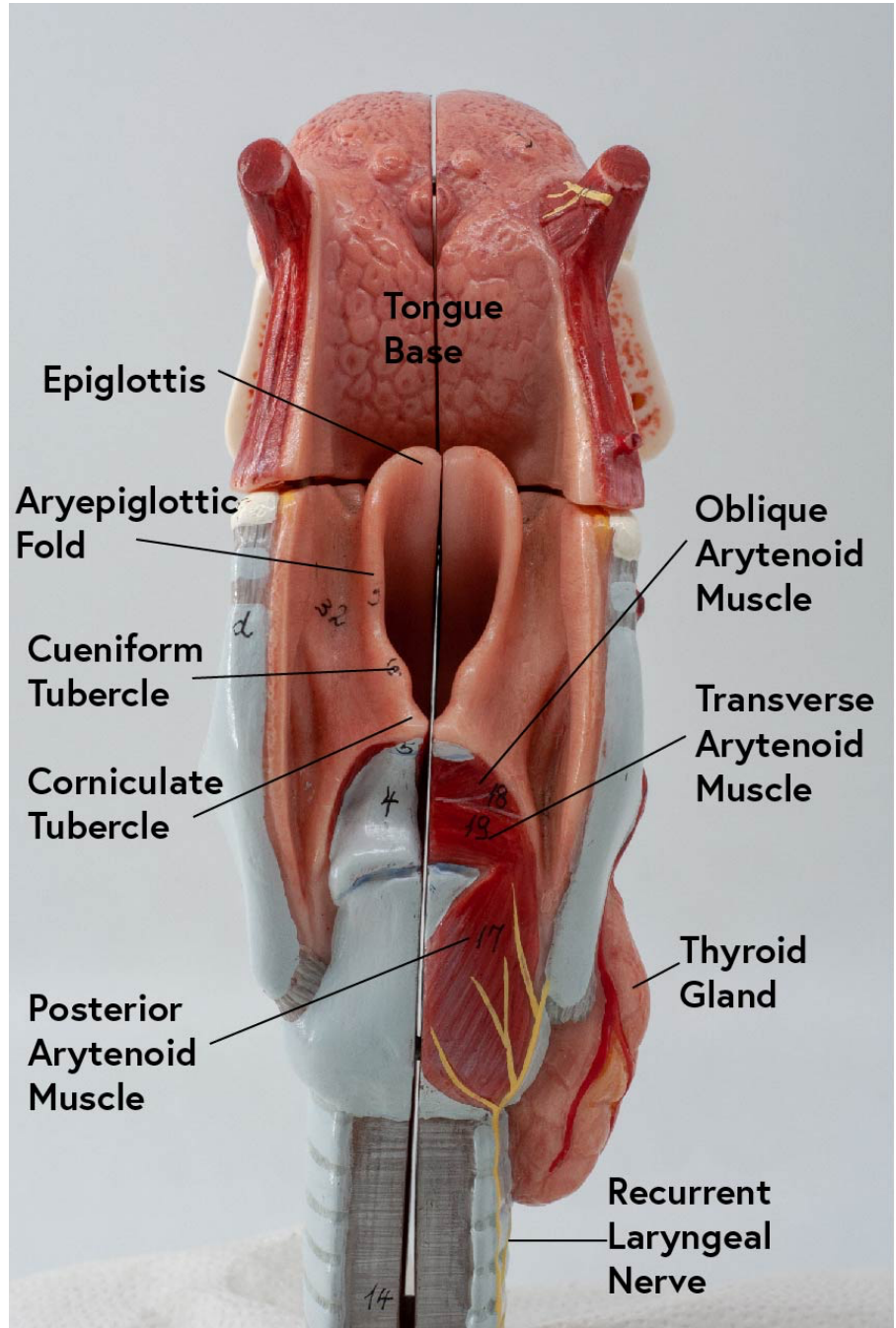
The muscles can be divided into **intrinsic** and **extrinsic** muscles.

The extrinsic muscles elevate and depress the larynx.

The intrinsic muscles control the **vocal cords**.

Blood supply

The blood supply is derived from the **external carotid** and **subclavian** artery.



Posterior view of the Larynx

The Nerve Supply

Nerves supplying the movement and sensation of the larynx originate from the **vagus nerve** via the **superior laryngeal nerve** and **recurrent laryngeal nerve**.

The mucosa of the larynx above the cords is supplied by the internal branch of the superior laryngeal nerve; below the cords the mucosa is innervated by the recurrent laryngeal nerve.

The **recurrent laryngeal nerve** supplies all the intrinsic muscles of the larynx, apart from **cricothyroid muscle** which is innervated by the external branch of the superior laryngeal nerve.

