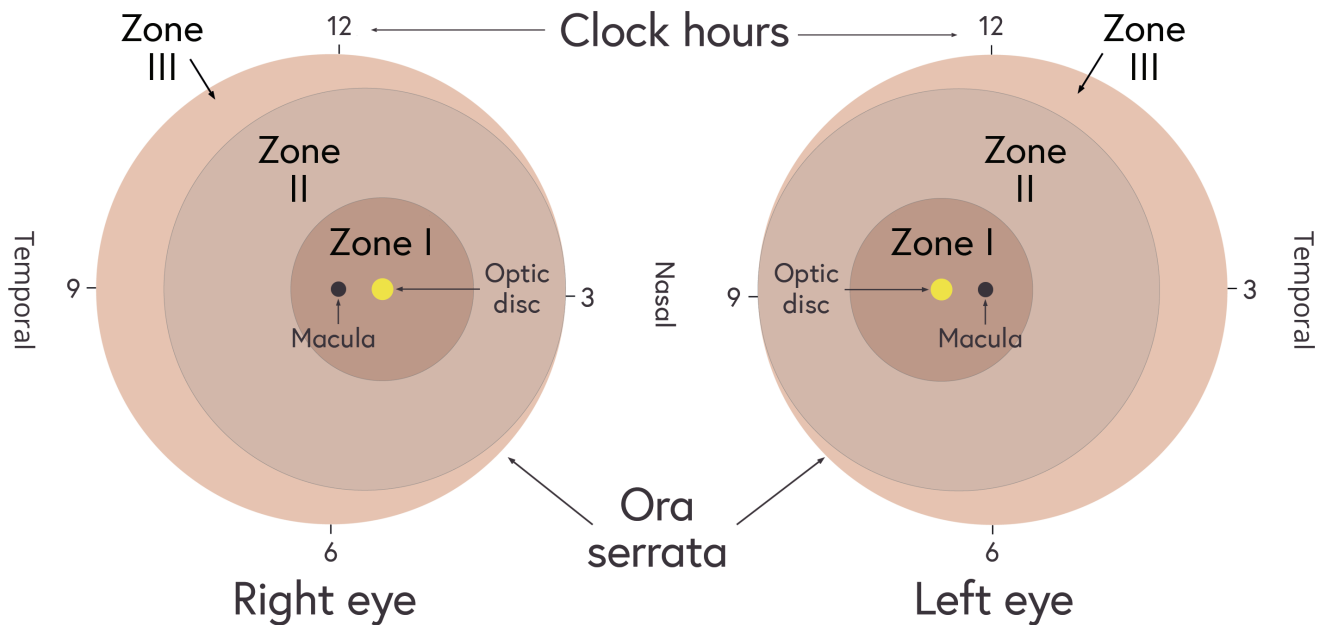
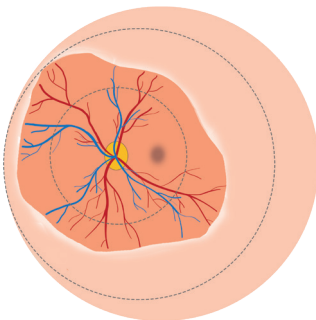


# Job aid: ROP classification and decision making

## ZONES (SITE)

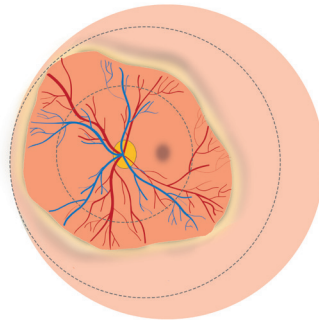


## STAGES



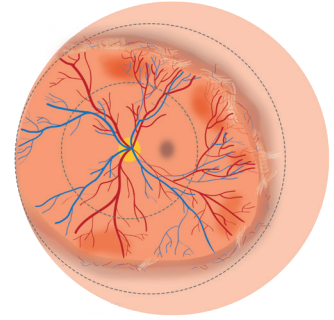
### Stage 1

Demarcation line  
between vascular and  
avascular retina



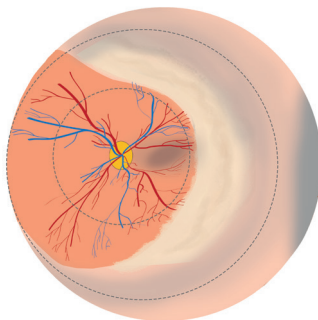
### Stage 2

Raised ridge



### Stage 3

Vascularised ridge

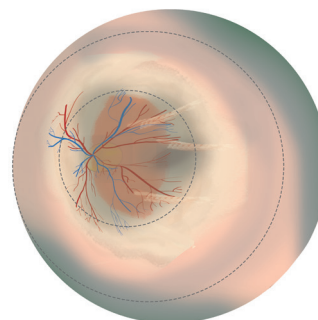


### Stage 4

Subtotal retinal detachment:

4a) Macular not detached

4b) Macular detached (as shown)



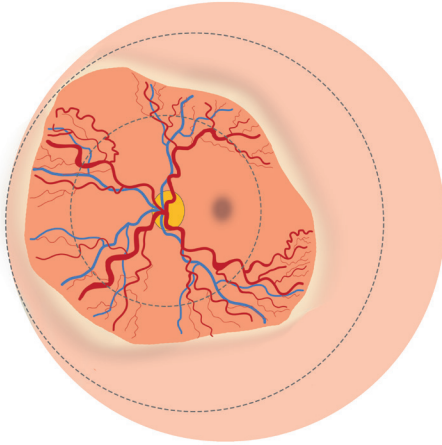
### Stage 5

Total retinal detachment:

5a) Open funnel

5b) Closed funnel (as shown)

## PLUS DISEASE



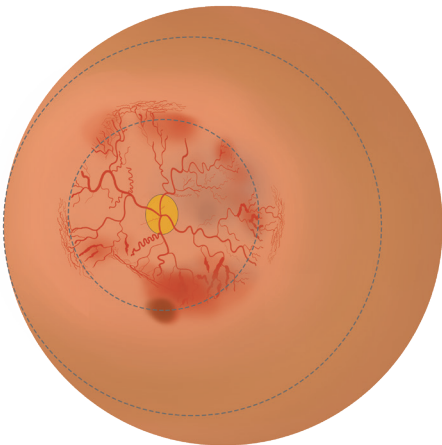
Signs of '**plus**' disease:

- Retinal vessels dilated and tortuous in all four quadrants
- Iris vascular engorgement (dilated)
- Poor pupillary dilatation
- Vitreous haze

Signs of '**pre-plus**' disease:

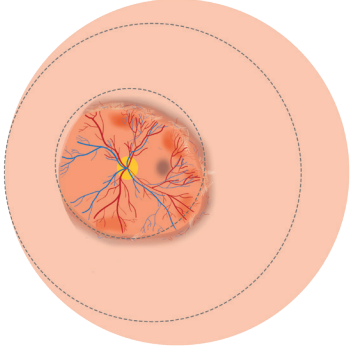
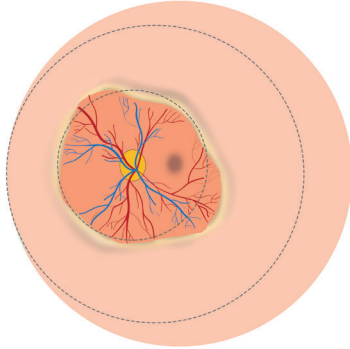
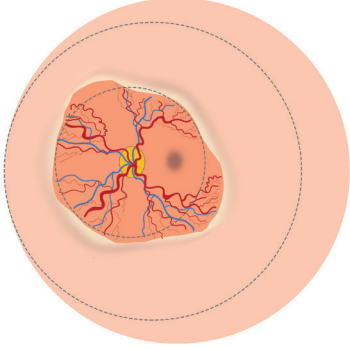
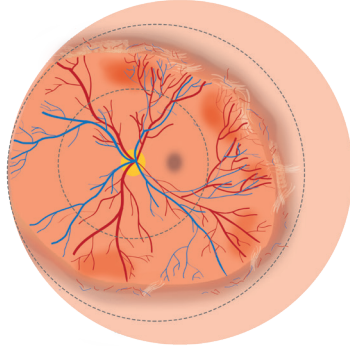
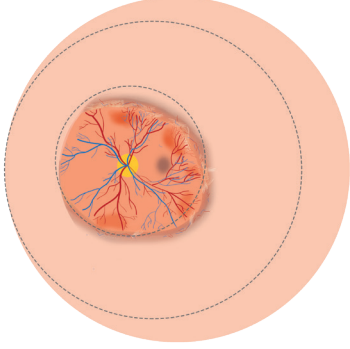
- Vessels dilated and more tortuous than normal

## AGGRESSIVE POSTERIOR ROP



- Prominent plus disease
- Ill-defined demarcation line
- Flat network of proliferating new vessels
- Difficult to differentiate between arterioles and venules
- Progression is not through classic stages 1 to 3

# TYPES OF ROP TO SUPPORT MANAGEMENT DECISIONS

Type 1 ROP	Type 2 ROP
HIGH RISK ROP	LOW RISK ROP
 <p>Zone 1 Stage 3 <b>without</b> plus disease</p>	 <p>Zone 1 Stage 1 or 2 <b>without</b> plus disease</p>
 <p>Zone 1 any stage <b>with</b> plus disease</p>	 <p>Zone 2 Stage 3 <b>without</b> plus disease</p>
 <p>Zone 2 Stage 2 or 3 <b>with</b> plus disease</p>	
<b>Treatment required within 24 - 48 hours</b>	<b>Follow up screening required</b>