


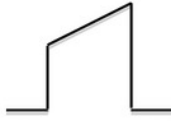


“Hats and caps” guide to capnography traces on intensive care:

Flat trace wrong place

Posh hats are good!

Bad	Good
 <p>Dunce hat – bad</p> <p>Indicates – significant leak</p>	 <p>Top hat – good</p> <p>Indicates – clear unobstructed airway</p>
 <p>No hat – very bad</p> <p>Indicates – dislodged/displaced tracheal tube or tracheostomy</p> <ul style="list-style-type: none">- oesophageal intubation- lack of ventilation	 <p>Ascot hat – OK</p> <p>Indicates – bronchospasm - partially obstructed airway</p>

Cook TM, Kelly FE, Goswami A. Hats and Caps, capnography training on intensive care. Anaesthesia 2013; 68:421



Wrong



Right!